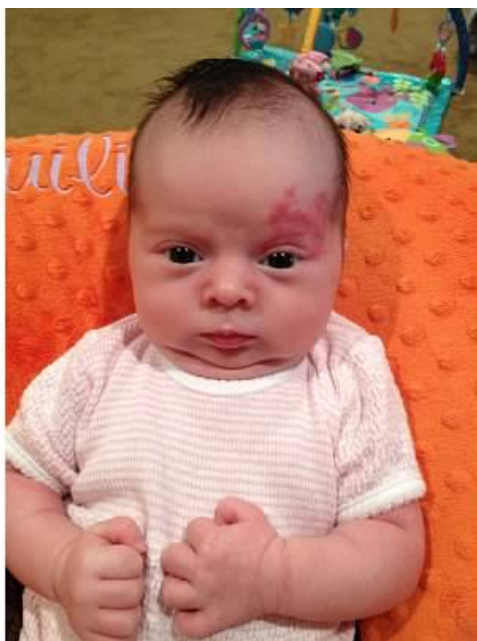

Guilianna's Story

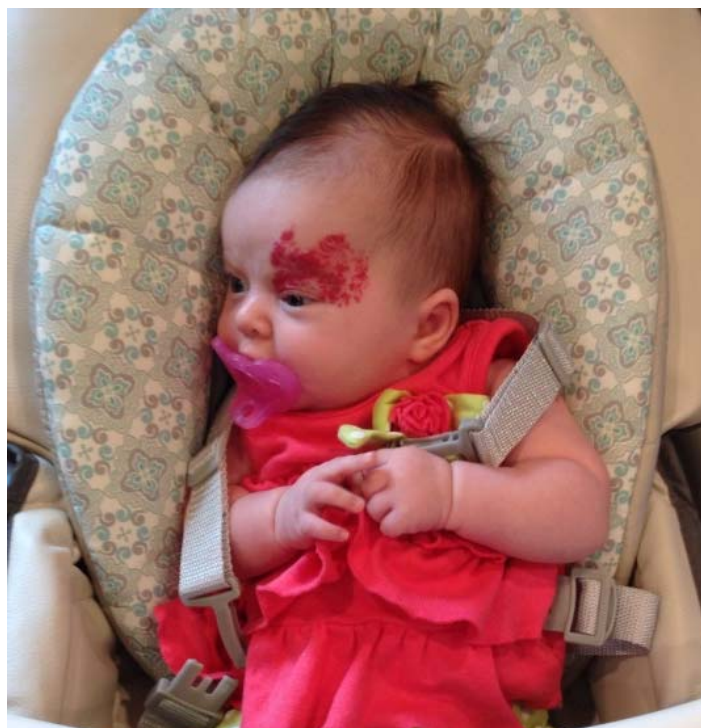When Guilianna was born there was no indication of a vascular malformation on her face. It wasn't until her first initial check-up after birth that we even realized there was a pink tint to the skin around her left eye. At this time her former pediatrician mis-diagnosed her vascular malformation as a Port Wine Stain. Because of the way he chose to handle the situation we decided to get a second opinion. We switched to our current Pediatrician that was sure it wasn't Port Wine, but wanted us to take a wait and see approach. We looked at it weekly, and watched the light pink gradually turn to red. Over a period of 48 hours at around 6 weeks of age the redness darkened drastically and started to become raised. It would be two days before we could see our pediatrician. I took to the internet and this is where I found the Vascular Birthmark Foundation.



At Birth



At 2 weeks



At 8 weeks

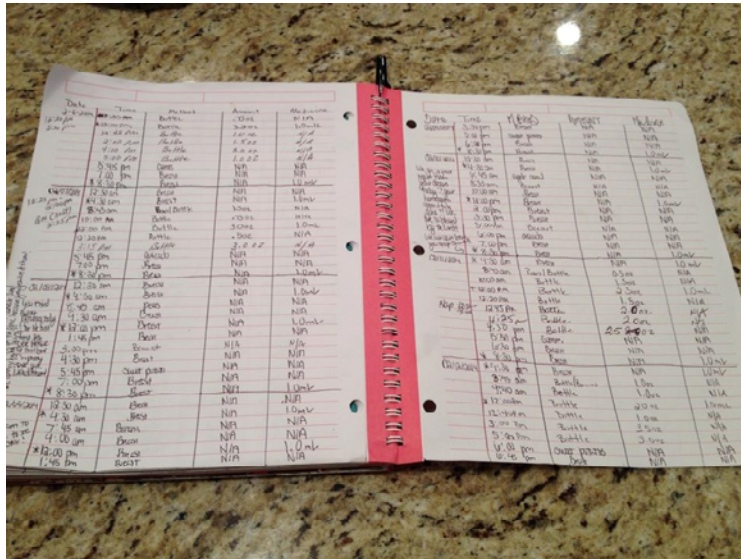


At 10 weeks (just after starting propranolol)

At this point we had never heard of a hemangioma. During the research I had done every hemangioma I saw looked like one large tumor. Ours was spread out and speckled. Without knowing where to turn I contacted Dr. Stuart Nelson, the VBF expert on Port Wine. Within 24 hours Dr. Nelson responded to my email. He told us that she did in fact have a hemangioma, a segmented hemangioma of infancy. He mentioned we needed to see a specialist as soon as possible. As first time parents my husband and I were terrified, but were relieved to finally have an answer. We saw our pediatrician the next day.

The next step in our journey was being sent to a specialist, Dr. Amy Theos, at Children's Hospital of Alabama. Dr. Theos prescribed us propranolol, which we would be on for the next year. The Vascular Birthmark Foundation provided excellent support and information as we began our journey to keep the hemangioma's growth at bay. By the time we started receiving treatment she was already having difficulty opening her eye. Her eyesight was at risk so

there was no question as to whether or not we would begin the medication. Luckily, we had no adverse side effects to the propranolol.



Our "Book"

Over the next year we wrote down every feeding, and for a breastfed baby this was a lot. We wrote down every time she got her medication. We kept up with everything in a book, and we are proud to say that she never one time missed her medication. After two weeks of being on propranolol she was already able to open her eye better. We continued to see the hemangioma regress over the next year. The week after her first birthday we began the process of weaning off of the medicine. Although there was a slight increase in redness due to the increase in blood flow we saw no more growth. She will be two in July.



Our “After” at 1 Year



And this is our silly little girl today!

There is still some slight redness around the area, but we just refer to it as her “beauty mark.” To be honest, it is hardly even noticeable. We were very blessed in that she suffered no permanent damage to her eye or eyesight.

We are so thankful for the Vascular Birthmark Foundation for all that they do to support our very special community of children and their families. We pray that by sharing Guilianna’s story we are able to help inform and educate others.

Thank you and God Bless,

Lance and Misti