



Diagnosis and Management of Infantile Hemangioma: Executive Summary

David H. Darrow, MD, DDS, Arin K. Greene, MD, Anthony J. Mancini, MD, Amy J. Nopper, MD, the SECTION ON DERMATOLOGY, SECTION ON OTOLARYNGOLOGY–HEAD & NECK SURGERY, AND SECTION ON PLASTIC SURGERY

FREE

This document is copyrighted and is property of the American Academy of Pediatrics and its Board of Directors. All authors have filed conflict of interest statements with the American Academy of Pediatrics. Any conflicts have been resolved through a process approved by the Board of Directors. The American Academy of Pediatrics has neither solicited nor accepted any commercial involvement in the development of the content of this publication.

Clinical reports from the American Academy of Pediatrics benefit from expertise and resources of liaisons and internal (American Academy of Pediatrics) and external reviewers. However, clinical reports from the American Academy of Pediatrics may not reflect the views of the liaisons or the organizations or government agencies that they represent.

The guidance in this statement does not indicate an exclusive course of treatment or serve as a standard of medical care. Variations, taking into account individual circumstances, may be appropriate.

All clinical reports from the American Academy of Pediatrics automatically expire 5 years after publication unless reaffirmed, revised, or retired at or before that time.

www.pediatrics.org/cgi/doi/10.1542/peds.2015-2482

DOI: 10.1542/peds.2015-2482

PEDIATRICS (ISSN Numbers: Print, 0031-4005; Online, 1098-4275).

Copyright © 2015 by the American Academy of Pediatrics

FINANCIAL DISCLOSURE: *The authors have indicated they do not have a financial relationship relevant to this article to disclose.*

POTENTIAL CONFLICT OF INTEREST: *The authors have indicated they have no potential conflicts of interest to disclose.*

INTRODUCTION

Infantile hemangiomas (IHs) are the most common tumors of childhood. Unlike other tumors, they have the capacity to involute after proliferation, often leading primary care providers to assume they will resolve without intervention or consequence. However, a subset of IHs may be associated with complications, resulting in pain, functional impairment, or permanent disfigurement. As a result, the primary care provider is often called on to decide which lesions should be referred for early consultation with a specialist.

This document provides a summary of the guidance contained in the clinical report “Diagnosis and Management of Infantile Hemangioma,” published concurrently in the online version of *Pediatrics* (*Pediatrics*. 2015;136[4]:e1060–e1104, available at: www.pediatrics.org/content/136/4/e1060.full). The report is uniquely based on input from the many specialties involved in the treatment of IH. Its purpose is to update the pediatric community about recent discoveries in IH pathogenesis, clinical associations, and treatment and to provide a knowledge base and framework for clinical decision-making in the management of IH.

NOMENCLATURE

- *Infantile hemangiomas* (IHs) are vascular neoplasms characterized by abnormal proliferation of endothelial cells and aberrant blood vessel architecture. In contrast, *vascular malformations* are structural anomalies and inborn errors of vascular morphogenesis. The latter include capillary malformations (port wine stains), venous malformations, lymphatic malformations (formerly known as lymphangiomas or cystic hygromas), and arteriovenous malformations.
- Congenital hemangiomas are biologically and behaviorally distinct from IHs. They are fully grown at birth and present as 2 varieties: rapidly involuting (RICH) and noninvoluting (NICH).
- Pyogenic granuloma, or lobular capillary hemangioma, is a reactive proliferative vascular lesion. Although classified with the vascular neoplasms and often misdiagnosed as IH, pyogenic granuloma is distinct in its clinical appearance and behavior.

- Lesions diagnosed as “cavernous hemangiomas” are usually, in fact, deep IHs or venous malformations.
- Kasabach–Merritt phenomenon (a consumptive coagulopathy) is not associated with IH but rather with other vascular neoplasms (kaposiform hemangioendothelioma and tufted angioma).

EPIDEMIOLOGY

- The incidence of IH is estimated at approximately 5% of infants, and the female/male ratio ranges from 1.4:1 to 3:1.
- IH risk factors include white race, prematurity, low birth weight, advanced maternal age, multiple gestation pregnancy, placenta previa, and preeclampsia. Other risk factors may include in utero diagnostic procedures (chorionic villus sampling and amniocentesis), use of fertility drugs or erythropoietin, breech presentation, and being first born.

PATHOGENESIS AND HISTOPATHOLOGY

- The pathogenesis of IH remains to be clearly elucidated. Both intrinsic factors (such as angiogenic and vasculogenic factors) and extrinsic factors (including tissue hypoxia and developmental field disturbances) probably contribute to development of IH.
- Endothelial progenitor cells may develop into IH from clonal expansion, resulting in vasculogenesis; alternatively, fetal progenitor cells arising from disruption of the placenta during gestation or birth may give rise to these tumors.
- A unifying theory suggests that IH results from aberrant proliferation and differentiation of a pluripotent progenitor cell, which migrates to locations in which growth of placenta-like tissue is favorable.
- Proliferative IHs histologically reveal well-defined masses of capillaries lined by plump endothelial cells, arranged in lobules, often

with enlarged draining veins. Involuting IHs reveal fibrofatty stroma, residual “ghost” vessels, mast cells, and apoptotic bodies.

- Immunohistochemical staining of IH is positive for glucose transporter 1 (GLUT1), CD31, CD34, factor VIII–related antigen, and others; GLUT1 is the most useful and widely used marker for the diagnosis of IH.

CLINICAL PRESENTATION

- IHs usually appear before 4 weeks of age and complete most of their growth by 5 months of age, although the proliferative phase may continue up to 12 months of age. Deep IHs tend to appear later and grow somewhat longer. The involution phase usually begins between 6 and 12 months of age, and the majority of regression occurs before 4 years of age. As IHs involute, they flatten and shrink, with fading of their color.
- Up to 70% of IHs leave behind residual skin changes, including telangiectasia, fibrofatty tissue, redundant skin, atrophy, dyspigmentation, and scar (especially in lesions with history of past ulceration).
- Premonitory findings in early IH include localized blanching of skin and macular telangiectatic erythema.
- During the proliferative phase, IHs may be classified based on their depth, as follows (Fig 1):
 - Superficial IH: Surface appears red, and there is little or no discernible subcutaneous component.
 - Deep IH: Surface appears blue or flesh-colored, and the tumor resides deep below the skin surface.
 - Combined IH: both superficial and deep components.
- Abortive (arrested growth, minimal growth, nascent) IH (Fig 2) presents as a telangiectatic patch

that does not uniformly proliferate.

- IHs may also be classified according to their anatomic configuration:
 - Localized (focal) IH: discrete lesions, arise from single focal point
 - Segmental IH (Fig 3): larger lesions, usually plaque-like, covering regions probably determined by neuroectodermal placodes
 - Indeterminate IH: cannot definitively be categorized as localized or segmental
 - Multifocal IH: focal lesions occurring at more than 1 anatomic site; may be a marker for hepatic IH when 5 or more cutaneous lesions are present
- Segmental IH may be associated with extracutaneous manifestations.
- A small subset of children with IH present with congenital anomalies recognized as clinical associations. These include:
 - PHACE, which is a congenital vasculopathy with features of *Posterior fossa defects, Hemanangiomas, cerebrovascular Arterial anomalies, Cardiovascular anomalies including Coarctation of the aorta, and Eye anomalies.* In PHACE, the IH is large and segmental, characteristically located on the face, scalp, or neck.
 - LUMBAR, which refers to *Lower body IH and other cutaneous defects, Urogenital anomalies and Ulceration, Myelopathy, Bony deformities, Anorectal malformations, Arterial anomalies, and Renal anomalies.* The associated IHs are usually segmental lumbosacral or anogenital lesions. LUMBAR, also described under the acronyms “SACRAL” and “PELVIS,” may be thought of as the “lower half of the body” variant of PHACE.

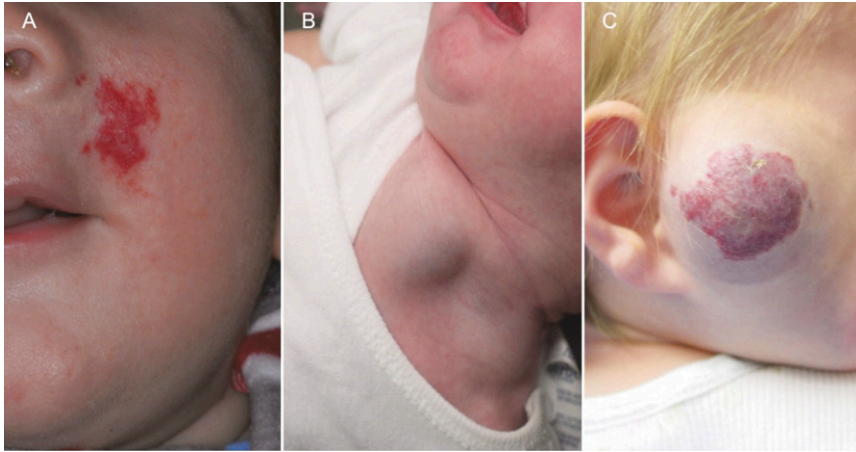


FIGURE 1
Cutaneous IHs can be classified based on their depth. A, *Superficial* IHs are visible only at the skin surface and may be focal (as shown here) or segmental. B, *Deep* IHs have no surface involvement. C, *Mixed*, or *compound*, IHs have both superficial and deep components.

COMPLICATIONS

- A minority of IH (up to 24% referred to pediatric dermatologists) may develop function-threatening or life-threatening complications, including:
 - Ulceration: most common IH complication, occurring in 16% of patients in 1 large series; risk factors include larger lesions, segmental IH, and distribution in the head, neck, perioral, and perineal or perianal locations
 - Bleeding
 - Visual impairment: associations include ptosis, amblyopia, astigmatism
 - Feeding impairment: most often associated with IH on the lips or in the aerodigestive tract
- Auditory impairment
- Nasal deformities
- Congestive heart failure: may occur with large IHs, as a result of arteriovenous shunting
- Airway obstruction: risk of airway IH increased with facial IH in the “beard” distribution
- Hypothyroidism: may be associated with diffuse hepatic IH; caused by excess production of type 3 iodothyronine deiodinase
- Segmental IHs are much more likely to develop complications (usually ulceration) than localized IH.
- Facial IHs are complicated more frequently than nonfacial IHs.

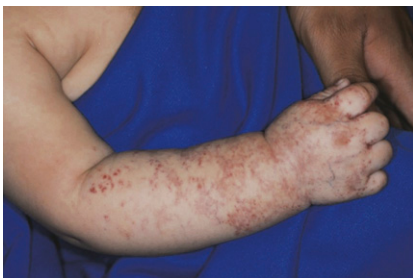

FIGURE 2
Abortive IHs are macular, telangiectatic patches that have failed to fully proliferate.

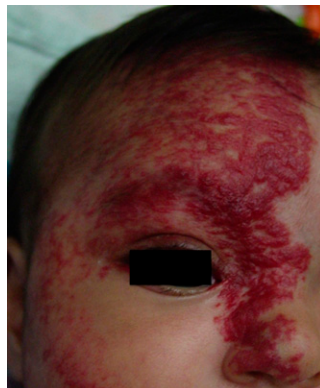

FIGURE 3
Segmental IH of the face.

IMAGING

- Imaging of IH is not usually necessary.
- Imaging may be necessary when the diagnosis is uncertain, when evaluation of extent is necessary, when the IH is a possible marker of PHACE or LUMBAR syndrome, or when response to therapy must be monitored.
- When imaging of IH is performed, ultrasound is the preferred modality for diagnosis, whereas MRI is better to assess extent of the lesion.

CLINICAL APPROACH TO IH

- The indications for intervention for IH include:
 - Emergency treatment of potentially life-threatening complications
 - Urgent treatment of existing or imminent functional impairment, pain, or bleeding
 - Evaluation to identify important structural anomalies potentially associated with IH
 - Elective treatment to reduce the likelihood of long-term or permanent disfigurement
- There is no algorithm to determine the most appropriate modality and timing of intervention for a given IH. Factors affecting this choice include:
 - Age of the patient
 - Growth phase of the lesion
 - Location and size of the lesion
 - Degree of skin involvement
 - Severity of complications and urgency of intervention
 - Potential for adverse psychosocial consequences
 - Parental preference
 - Physician experience

MANAGEMENT OF ULCERATED IH

- Treatment recommendations for ulcerated IH are based largely on

expert opinion; high-quality studies of interventions and evidence-based guidelines are lacking.

- Ulcerated IH management is focused on wound care, pain control, controlling IH growth, and prevention and treatment of secondary infection. Vigilant wound care and use of barrier ointments or dressings, as well as topical antibiotics, are generally considered first-line therapy for ulcerated IH.
- For ulcerated IH with suboptimal response to conservative topical care, additional medical or surgical interventions may be needed. There is growing evidence that propranolol may be effective in treating severe ulcerated IH. In addition, pulsed-dye laser may also be helpful in treating persistent ulceration. Rarely, surgical intervention may be indicated in recalcitrant ulcerations.

MEDICAL THERAPY FOR IH

- Systemic corticosteroids were the mainstay of therapy from the 1960s until a 2008 report of serendipitous improvement of IH in infants treated with β -blocker therapy (propranolol).
 - β -blocker therapy:
 - The mechanism of action of propranolol, a nonselective blocker of β -adrenergic receptors that has been used to treat cardiac disorders, is not fully understood. Proposed mechanisms of action include vasoconstriction, inhibition of angiogenesis, downregulation of matrix metalloproteinases and interleukin-6, regulation of the renin-angiotensin system, and inhibition of nitric oxide production.
 - An oral formulation of propranolol (Hemangeol [Pierre Fabre, Castres, France]) for treatment of IH received approval from the US Food and Drug Administration in March 2014. A large 2015 randomized controlled trial of Hemangeol in treatment of IH showed effectiveness when dosed at 3.4 mg/kg per day for 6 months.
 - Contraindications to propranolol therapy include cardiogenic shock, sinus bradycardia, hypotension, heart block greater than first degree, heart failure, asthma or reactive airway disease, and known hypersensitivity to the drug. Special precautions have been suggested for children with PHACE syndrome who have high-risk intracranial vascular anomalies.
 - Recommendations for pretreatment assessment and the optimal setting for therapy initiation continue to evolve and vary between clinicians. A complete history and physical examination with special attention to the cardiac and pulmonary systems aids in assessing a child's candidacy for propranolol initiation. Although some clinicians obtain pretreatment electrocardiogram or cardiology consultation before starting propranolol, the value of such screening in patients with an unremarkable cardiac history and examination is uncertain.
 - A consensus report recommends initiation of propranolol therapy in a clinic setting with cardiovascular monitoring hourly for 2 hours after initiation and recommends repeat monitoring for dosage increases of >0.5 mg/kg per day for infants >8 weeks of age. Inpatient initiation of propranolol is considered for infants <8 weeks of age or infants with post-conceptual age <48 weeks and for infants with decreased social support or increased risk factors.
 - Recommended administration of propranolol is 1 to 3.4 mg/kg per day divided into 2 or 3 doses. Duration of therapy is usually until 8 to 12 months of age, or between 3 and 12 months of therapy, depending on age of initiation and clinical response.
- Rebound growth after discontinuation of therapy is reported in 5% to 25% of patients; therefore, some clinicians wean propranolol over a number of weeks or months.
- Common adverse effects of propranolol include sleep disturbance, cold hands and feet, diarrhea, and bronchial hyperreactivity. Rare adverse effects include bradycardia and hypotension, which are generally asymptomatic, and severe hypoglycemia, which may be associated with decreased responsiveness or seizures.
 - Precautions that may reduce the risk of hypoglycemia with propranolol therapy include administration of medication after feeding; holding doses when the patient is ill with decreased oral intake, vomiting, or diarrhea; and avoiding prolonged intervals of longer than 6 hours between feedings.
 - A number of case reports and case series have reported successful use of topical timolol, a β -blocker used to treat glaucoma, in the treatment of uncomplicated *superficial* IH. Timolol 0.5% gel-forming solution has less systemic absorption than timolol in solution.
 - Corticosteroid therapy:
 - For patients with contraindications or inadequate response to propranolol therapy, corticosteroids may be an effective treatment alternative. Most studies support dosing with oral prednisolone or prednisone at 2 to 3 mg/kg per day given in a single morning dose. Several months of therapy is generally necessary; treatment is more likely to be successful when initiated during IH proliferation.
 - Long-term corticosteroid therapy may be associated with many adverse effects, including irritability, sleep disturbance, gastric

irritation, hypertension, immunosuppression, hypothalamic–pituitary–adrenal axis suppression, linear growth deceleration, and cushingoid facies. These adverse effects are more frequently seen with higher doses and prolonged therapy and tend to be reversible. Periodic monitoring for potential toxicity, especially blood pressure elevation and decreased rate of growth, is recommended.

- Intralesional steroid injections are often effective in treating small, bulky, well-localized IH lesions. However, although adverse systemic effects have been reported rarely, intralesional steroids may be systemically absorbed, especially when given in larger doses or multiple injections, and optimal dosing and safety profile are not well studied. As a result, this modality is no longer considered first-line therapy for most IHs. High-potency topical steroids have been reported as effective in the treatment of small superficial IH, although their use is largely being replaced by treatment with topical β -blockers.
- **Other medical therapies:**
 - Medications other than β -blockers and corticosteroids may have efficacy in treating IH, but their utility is limited by their safety profile. Interferon- α appeared to be a promising treatment option in the 1980s and early 1990s, but studies showing significant neurotoxicity have generally precluded this treatment modality for IH.

LASER TREATMENT OF IH

- Laser treatment of IH may be useful in treating early non-proliferating superficial lesions, salvaging critical skin, controlling ulceration, and treating persisting postinvolution telangiectasia. Laser therapy may also be used as

a component of multimodal therapy.

- The pulsed-dye laser is used most commonly, because its light is preferentially absorbed by hemoglobin.
- Some studies suggest that the use of the pulsed-dye laser on proliferating and segmental IHs may lead to ulceration. Atrophic scarring and hypopigmentation are also potential complications of laser use in IH.

SURGICAL THERAPY FOR IH

- Resection of a proliferating IH generally is not recommended, because younger patients are at greater risk of anesthetic morbidity, blood loss, and iatrogenic injury than those who undergo operative intervention later in childhood. Indications for excising a hemangioma during infancy include failure of other therapy for a critical IH, a focal lesion in a favorable location, or elective surgery leaving a scar that would be the same if the lesion were removed after involution.
- Delaying surgery until after infancy allows the lesion time to involute, becoming smaller and less vascular. Consequently, the procedure is safer, and often the patient has a shorter scar and a higher likelihood of a favorable outcome. However, most IHs do not improve significantly beyond 4 years of age, and surgery by this age corrects the deformity before self-esteem and long-term memory are well established.
- Because hemangiomas usually expand the skin, after they are removed the wound usually can be reconstructed by linear closure. Skin grafts and local flaps are rarely needed.
- Because IH is benign, the entire lesion does not need to be extirpated. The goal is to improve the appearance of the child, and

subtotal excision often is performed intentionally.

- For circular lesions located on the face, the length of the scar can be minimized by circular excision and purse-string closure. This procedure also minimizes distortion of surrounding structures and may require a second stage to convert a circular scar into a line.

IHs WITH SPECIAL ANATOMIC CONCERNS

- IHs involving the eyelids can deform the cornea and obstruct the visual axis, causing astigmatism, strabismus, or amblyopia. Early evaluation by a pediatric ophthalmologist and early intervention may reduce the risk of complications and sequelae.
- Propranolol has largely supplanted intralesional steroid injection for treating problematic IHs of the upper eyelid because the risk of blindness from embolization of the retinal artery. However, intralesional steroids are an alternative for refractory lesions. Topical β -blockers may be useful for intraocular IHs.
- IHs of the airway may occur in isolation, but patients with large cutaneous lesions involving the lower face and neck (the so-called “beard” distribution) are at greater risk. Most lesions are subglottic, and patients so affected can have biphasic stridor and barking cough that are often mistaken for croup. Operative endoscopy is generally necessary to identify the lesions and assess their extent. Symptomatic lesions are generally treated with propranolol, but patients who do not respond rapidly may be candidates for dilation, intralesional corticosteroid injection, or partial resection. Open resection has become less commonly indicated since introduction of propranolol therapy for IH.

- Early management of nasal tip IH using some combination of pharmacotherapy and laser reduces the likelihood of long-term deformity from skin expansion and atrophy and of injury to the underlying cartilage. Reconstruction of involuted nasal tip IHs is often necessary even with aggressive early intervention and includes excision of the lesion, reconstruction of the cartilaginous framework, and excision and redraping of the skin.
- IHs involving the lips and perineum, especially segmental lesions, have a higher risk of ulceration; early pharmacotherapy may be effective in avoiding this complication. Reduction of friction on perineal IHs using topical lubrication with or without a barrier dressing may help prevent ulceration.
- IHs located within the vermilion area of the lip can be removed with a transverse mucosal incision, although some deep lesions are best approached through the vermilion-cutaneous border. Bulkier lesions that cause lengthening of the lip and those that cross the vermilion-cutaneous border are best addressed with a wedge excision. Eversion of the lower lip can be corrected by excision of a mucosal strip, and correction of inversion may require a lyophilized dermal implant or dermal graft.
- The liver is the most common location of visceral hemangiomas:
 - Infants with ≥ 5 cutaneous hemangiomas are at greater risk of hepatic lesions and are candidates for screening by ultrasonography.
 - Liver hemangiomas can be focal, multifocal, or diffuse. Focal lesions are actually RICHs that are fully grown at birth and rapidly involute over the first year of life. Multifocal and diffuse lesions are true infantile

hemangiomas and often coexist with cutaneous lesions. Symptomatic multifocal and diffuse lesions can be treated with systemic pharmacotherapy.

- Infants with significant multifocal or diffuse hemangiomas should undergo thyroid hormone screening because the tumor can deactivate thyroid hormone. Hormone replacement may be necessary.
- Diffuse lesions may present with hepatomegaly and cause abdominal compartment syndrome.

CONCLUSIONS

Although many IHs can be observed without treatment, others will clearly benefit from medical or surgical intervention. When complications are likely or the threshold for intervention is uncertain, referral to an experienced specialist or a multidisciplinary vascular anomaly center may be advantageous. It is important for providers of pediatric care to keep abreast of advances in IH management as continued research leads to pathogenesis-directed therapeutic options and as the types of intervention and their use evolve.

LEAD AUTHORS

David H. Darrow, MD, DDS, FAAP
 Arin K. Greene, MD, FAAP
 Anthony J. Mancini, MD, FAAP
 Amy J. Nopper, MD, FAAP

CONTRIBUTING AUTHORS

Richard J. Antaya, MD, FAAP (Dermatology)
 Bernard Cohen, MD, FAAP (Dermatology)
 Beth A. Drolet, MD (Dermatology)
 Aaron Fay, MD (Ophthalmology)
 Steven J. Fishman, MD, FAAP (Pediatric Surgery)
 Sheila F. Friedlander, MD, FAAP (Dermatology)
 Fred E. Ghali, MD, FAAP (Dermatology)
 Kimberly A. Horii, MD, FAAP (Dermatology)
 Manish N. Patel, DO (Radiology, Interventional Radiology)
 Denise W. Metry, MD (Dermatology)
 Paula E. North, MD (Pediatric Pathology)
 Teresa M. O., MD (Otolaryngology)

Jonathan A. Perkins, DO (Otolaryngology)
 Michael L. Smith, MD, FAAP (Dermatology)
 Patricia A. Treadwell, MD, FAAP (Dermatology)
 Milton Waner, MD (Otolaryngology, Facial Plastic Surgery)
 Albert C. Yan, MD, FAAP (Dermatology)

SECTION ON DERMATOLOGY EXECUTIVE COMMITTEE, 2014–2015

Bernard A. Cohen, MD, FAAP, Chairperson
 Richard J. Antaya, MD, FAAP, FAAP
 Anna L. Bruckner, MD, FAAP
 Kim Horii, MD, FAAP
 Nanette B. Silverberg, MD, FAAP
 Teresa S. Wright, MD, FAAP
 Albert C. Yan, MD, FAAP, FAAP, Chairperson-Elect
 Michael L. Smith, MD, FAAP, Ex Officio

FORMER SECTION ON DERMATOLOGY EXECUTIVE COMMITTEE MEMBER

Sheila F. Friedlander, MD, FAAP

STAFF

Lynn Colegrove, MA

SECTION ON OTOLARYNGOLOGY–HEAD AND NECK SURGERY EXECUTIVE COMMITTEE, 2014–2015

Charles Bower, MD, FAAP, Chairperson
 Christina Baldassari, MD, FAAP
 German Paul Digoy, MD, FAAP
 Andrew Hotaling, MD, FAAP
 Stacey Ishman, MD, MPH, FAAP
 John McClay, MD, FAAP
 Diego Preciado, MD, PhD, FAAP
 Kristina Rosbe, MD, FAAP
 Scott Schoem, MD, FAAP, Past Chairperson
 Jeffrey Simons, MD, FAAP
 Steven Sobol, MD, FAAP
 David Walner, MD, FAAP

STAFF

Vivian Thorne

SECTION ON PLASTIC SURGERY EXECUTIVE COMMITTEE, 2014–2015

Peter J. Taub, MD, FAAP, Chairperson
 Stephen B. Baker, MD, FAAP
 Arin K. Greene, MD, FAAP
 Timothy W. King, MD, MPH, FAAP
 Donald R. Mackay, MD, FAAP, Immediate Past Chairperson
 Delora L. Mount, MD, FAAP, Chairperson-Elect
 Jordon Philip Steinberg, MD, FAAP
 Mark M. Urata, MD, DDS, FAAP, Vice Chairperson

STAFF

Kathleen Kuk Ozmeral

Diagnosis and Management of Infantile Hemangioma: Executive Summary
David H. Darrow, Arin K. Greene, Anthony J. Mancini, Amy J. Nopper and the
SECTION ON DERMATOLOGY, SECTION ON OTOLARYNGOLOGY–HEAD &
NECK SURGERY, AND SECTION ON PLASTIC SURGERY
Pediatrics 2015;136;786; originally published online September 28, 2015;
DOI: 10.1542/peds.2015-2482

Updated Information & Services	including high resolution figures, can be found at: /content/136/4/786.full.html
Subspecialty Collections	This article, along with others on similar topics, appears in the following collection(s): Dermatology /cgi/collection/dermatology_sub Section on Dermatology /cgi/collection/section_on_dermatology Section on Otolaryngology-Head and Neck Surgery /cgi/collection/section_on_otolaryngology-head_and_neck_surgery Section on Plastic Surgery /cgi/collection/section_on_plastic_surgery
Permissions & Licensing	Information about reproducing this article in parts (figures, tables) or in its entirety can be found online at: /site/misc/Permissions.xhtml
Reprints	Information about ordering reprints can be found online: /site/misc/reprints.xhtml

PEDIATRICS is the official journal of the American Academy of Pediatrics. A monthly publication, it has been published continuously since 1948. PEDIATRICS is owned, published, and trademarked by the American Academy of Pediatrics, 141 Northwest Point Boulevard, Elk Grove Village, Illinois, 60007. Copyright © 2015 by the American Academy of Pediatrics. All rights reserved. Print ISSN: 0031-4005. Online ISSN: 1098-4275.

American Academy of Pediatrics

DEDICATED TO THE HEALTH OF ALL CHILDREN™



PEDIATRICS®

OFFICIAL JOURNAL OF THE AMERICAN ACADEMY OF PEDIATRICS

Diagnosis and Management of Infantile Hemangioma: Executive Summary

David H. Darrow, Arin K. Greene, Anthony J. Mancini, Amy J. Nopper and the
SECTION ON DERMATOLOGY, SECTION ON OTOLARYNGOLOGY-HEAD &
NECK SURGERY, AND SECTION ON PLASTIC SURGERY

Pediatrics 2015;136;786; originally published online September 28, 2015;

DOI: 10.1542/peds.2015-2482

The online version of this article, along with updated information and services, is
located on the World Wide Web at:

</content/136/4/786.full.html>

PEDIATRICS is the official journal of the American Academy of Pediatrics. A monthly publication, it has been published continuously since 1948. PEDIATRICS is owned, published, and trademarked by the American Academy of Pediatrics, 141 Northwest Point Boulevard, Elk Grove Village, Illinois, 60007. Copyright © 2015 by the American Academy of Pediatrics. All rights reserved. Print ISSN: 0031-4005. Online ISSN: 1098-4275.

American Academy of Pediatrics

DEDICATED TO THE HEALTH OF ALL CHILDREN™

