

# Early Surgical Intervention for Proliferating Hemangiomas of the Scalp: Indications and Outcomes

Jason A. Spector, M.D.

Francine Blei, M.D.

Barry M. Zide, D.M.D., M.D.

New York, N.Y.

**Background:** Large hemangiomas of the scalp, though uncommon, present unique challenges to the reconstructive surgeon. If not treated early, these lesions can result in large areas of alopecia, distortion of the hairline, or deformation of the ear. Given these potential complications and the relative pliability and redundancy of the infant scalp before 4 months of age, the authors propose early surgical excision.

**Methods:** A retrospective review of the senior author's (B.M.Z.) patient records was performed; over a period of 4 years, six infants were identified who underwent resection of a large scalp hemangioma. The surgical planning and execution of each case and follow-up are detailed.

**Results:** All six hemangiomas were excised completely. In five cases, the excisions were performed in one stage at or before 4 months of age. In a sixth case, a tissue expander was placed before excision and closure in an 18-month-old infant. In three cases, significant ear malposition was corrected by removal of the deforming mass. There were no complications.

**Conclusions:** The authors have demonstrated that by taking advantage of the greater elasticity of the infant scalp, large hemangiomas of the scalp can be aggressively and successfully treated with surgical intervention, often in one operation. Beyond the usual indications, early surgical excision of scalp hemangiomas may be advantageous and warranted to prevent the development of large alopecic areas or the permanent distortion of the hairline and aural anatomy. (*Plast. Reconstr. Surg.* 122: 457, 2008.)

**H**emangiomas are common vascular tumors that usually develop within the first month of life or, less commonly, are present at birth.<sup>1</sup> The approach to the treatment of hemangiomas has been relatively dogmatic, based on the "observation" that the majority of hemangiomas will spontaneously "involute" by 5 to 7 years of age.<sup>2</sup> Given the high likelihood that the hemangioma will ultimately disappear (although not its potentially unaesthetic residual fibrofatty remnant), many medical practitioners will pursue no treatment beyond parental reassurance.<sup>3</sup> Intervention is deemed necessary only in certain grave circumstances as in the case of significant bleeding

from ulcerated lesions, large lesions causing either heart failure or significant thrombocytopenia, obstruction of the airway, or lesions of the gastrointestinal tract or visual or (bilateral) auditory axis.<sup>3-5</sup>

Although hemangiomas may present anywhere on or within the body, hemangiomas of the scalp deserve an approach different from that in other regions. When they are small, hemangiomas of the scalp do not require intervention. However, when they are large, scalp hemangiomas may cause worrisome complications such as ulceration, bleeding, or cardiac failure.<sup>6</sup> In other cases, although not immediately threatening to the health of the infant, large scalp hemangiomas may disrupt the anterior hairline or, as they involute, may result in a large zone of alopecia. A hemangioma extending into the parietal region may perma-

*From the Division of Plastic Surgery, Weill Cornell Medical College, the Department of Pediatrics, and the Institute of Reconstructive Plastic Surgery, Division of Plastic Surgery, New York University School of Medicine.*

*Received for publication January 17, 2007; accepted December 3, 2007.*

*Copyright ©2008 by the American Society of Plastic Surgeons*

DOI: 10.1097/PRS.0b013e31817d5fa2

**Disclosure:** The authors have no financial interests to disclose.

nently distort the aural anatomy if its deforming force is not removed.

To avert the potentially life-threatening or un-aesthetic consequences of large scalp hemangiomas, we propose that early surgical intervention should be encouraged. Because of the “accordion-like” laxity inherent within the scalp of infants younger than 4 months, extirpation of large lesions is feasible, often by primary closure, but sometimes requires a straightforward rotational scalp flap.<sup>7</sup> In this article, we describe six cases of large scalp hemangiomas and detail their successful surgical intervention.

### PATIENTS AND METHODS

A retrospective review of the senior author's (B.M.Z.) patient records was performed. Over a period spanning 4 years, five infants with large (>4 cm diameter) scalp hemangiomas underwent surgical excision, all before 4 months of age; a sixth patient was 18 months old at the time of surgery. Patients were followed for a minimum of 6 months after their last surgical procedure.

### CASE REPORTS

#### Case 1

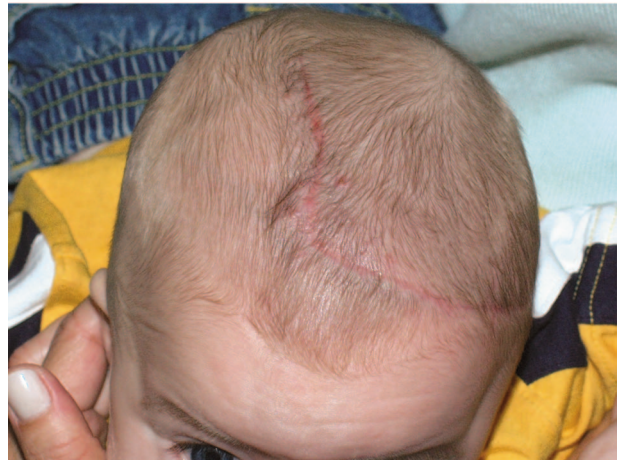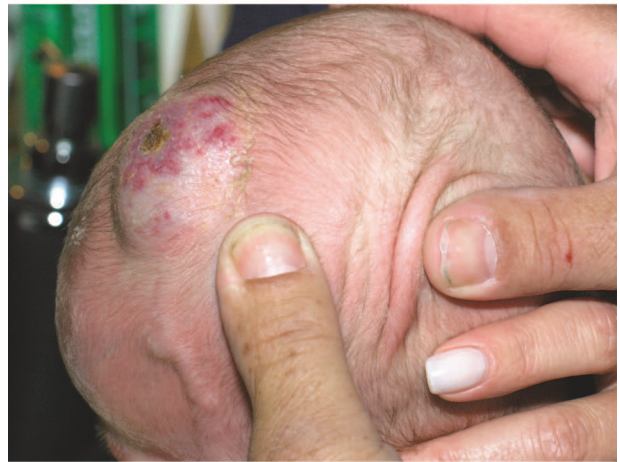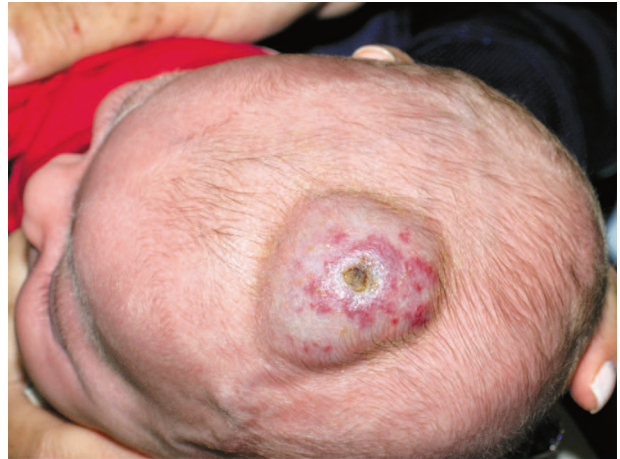An otherwise healthy 10-week-old infant presented to the office with a protuberant trapezoidal hemangioma near the vertex measuring approximately  $4 \times 4$  cm. There was a central area of ulceration (Fig. 1, *above*). To capitalize on the relative excess scalp tissue in infants younger than 4 months (Fig. 1, *center*), the patient was scheduled for excision of the lesion at 3 months of age.

After injection around the hemangioma with a dilute solution of epinephrine (1:400,000), the entire lesion was removed, keeping all incisions *outside of the lesion*. Dissection proceeded in the subgaleal plane; there was minimal blood loss. The resultant defect was closed primarily using a scalp rotation flap with a small backcut. Follow-up 6 months later demonstrates a well-healed incision that is completely hidden within the hairline (Fig. 1, *below*).

#### Case 2

An 18-month-old girl presented to the office with a bulky ( $6 \times 6$ -cm) sessile hemangioma involving the scalp and anterior hairline (Fig. 2, *above*). The size of the lesion had been stable for several months without any further decrease in size. Although the parents desired surgical excision of the lesion, it was clear that even in the unlikely scenario that the hemangioma involuted completely, a portion of the anterior hair-bearing scalp would be left alopecic.

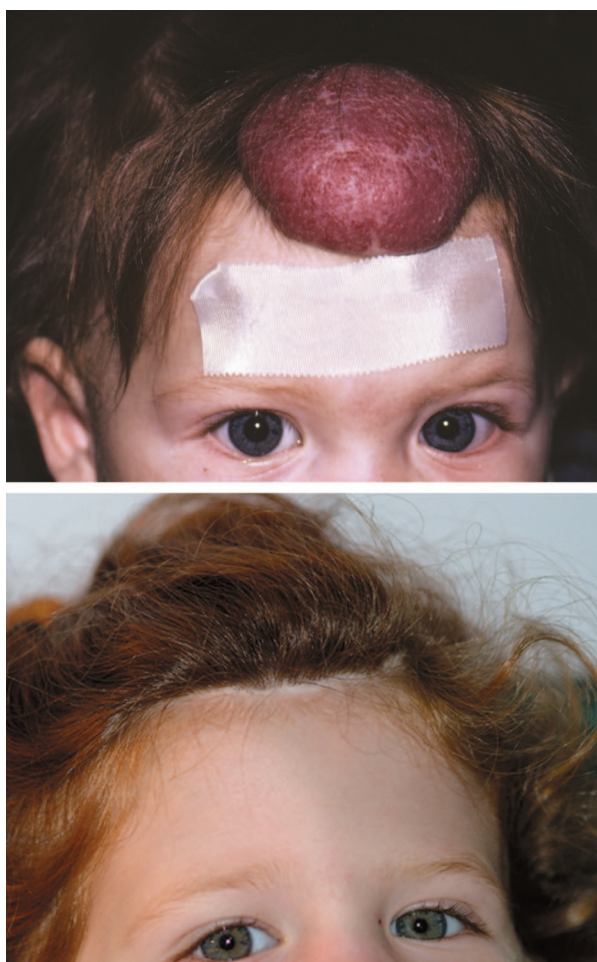An  $8 \times 6$ -cm tissue expander was placed through the hair-bearing scalp posterior to the lesion. After a  $2\frac{1}{2}$ -month expansion, the hemangioma was excised completely and the expanded skin was advanced into the forehead defect to recreate a natural appearing hairline. Follow-up 12 months after surgery demonstrates a well-healed incision with an aesthetically acceptable hairline (Fig. 2, *below*).



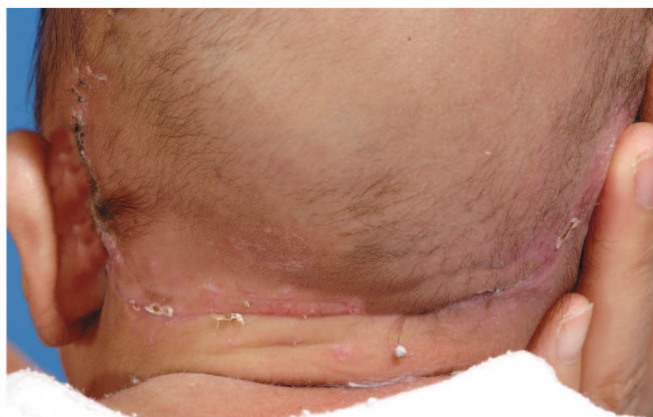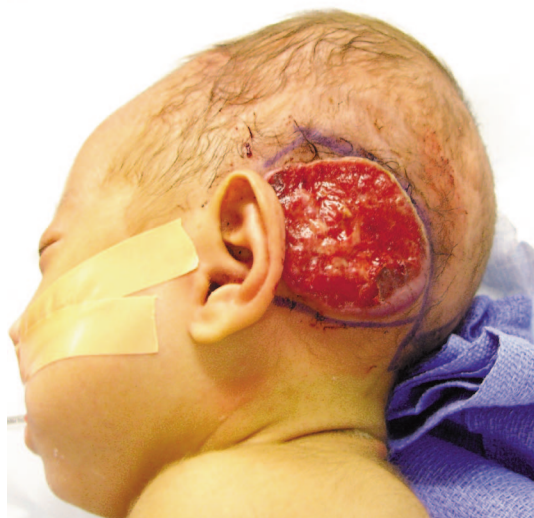**Fig. 1.** Case 1. (*Above*) Photograph of a large hemangioma of the vertex of the scalp with a central area of ulceration. (*Center*) Photograph demonstrating the accordion-like properties of the scalp in infants younger than 4 months. (*Below*) Photograph obtained 6 months postoperatively. Note that the scar is completely hidden within the hairline.

#### Case 3

A 4-month-old girl was referred for surgical excision of an enlarging ulcerated hemangioma of the left mastoid portion of



**Fig. 2.** Case 2. (Above) Photograph of a large hemangioma of the forehead involving the anterior hairline. (Below) After placement of a tissue expander, and expansion and excision of the lesion, a natural hairline has been created.



**Fig. 3.** Case 3. (Left) Photograph of a large ulcerating hemangioma of the left mastoid region. (Right) Postoperative view at 2 months demonstrating a well-healing scar placed along the posterior hairline.

the scalp measuring approximately  $4 \times 5$  cm. The patient had recently developed a significant bleed from the lesion, and the decision was made to perform complete surgical excision rather than treat the lesion with intralesional steroids (Fig. 3, *left*).

After infiltration with a dilute solution of epinephrine (1:400,000) in the subgaleal plane, hemostatic polypropylene sutures were placed anterior to the lesion to reduce blood inflow. As in case 1, the entire lesion was removed, with care taken to keep all incisions *outside of the lesion*. Dissection proceeded in the subgaleal plane; there was minimal blood loss. The resultant defect was closed primarily without tension by rotating a superiorly based scalp flap with a minimal backcut. The borders of the scalp rotation flap were kept almost completely within the occipital hairline. Figure 3, *right* demonstrates a well-healed incision that is camouflaged by its location along the occipital hairline.

#### Case 4

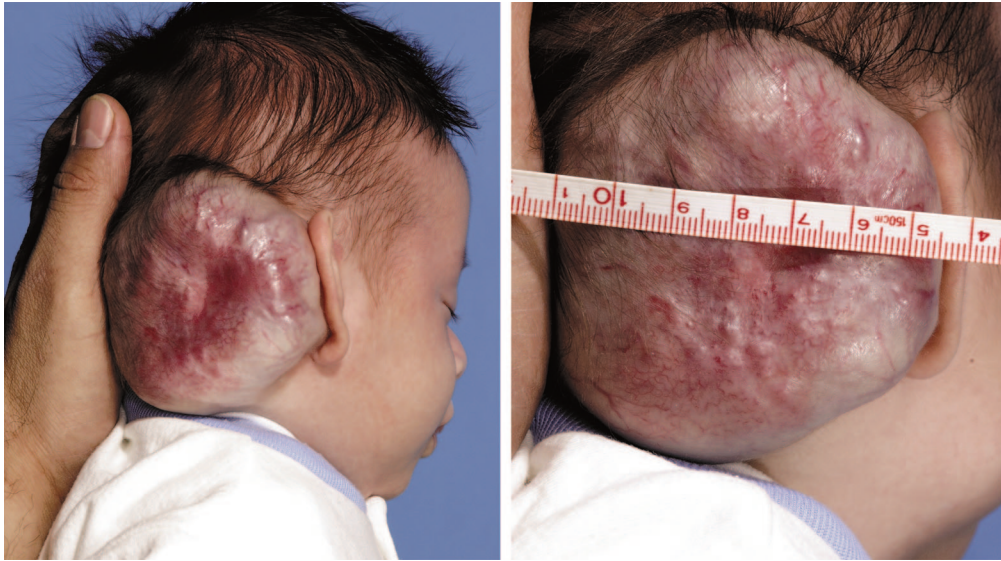A 4-month-old boy was referred for evaluation of a large  $8 \times 7$ -cm rapidly involuting congenital hemangioma (the base was slightly smaller) of the postauricular scalp that was causing a significant anterior distortion of the right external ear (Fig. 4).

After securing the airway, several interrupted "hemostatic" 3-0 polypropylene sutures were placed through the full thickness of the scalp between the ear and the lesion and along the anteroinferior border of the lesion. After infiltration below the lesion and adjacent tissues with a dilute solution of epinephrine in the subgaleal plane, an incision was made along the posterior border of the lesion but outside the lesion itself. The resection was carried out in the subgaleal plane, stopping just posterior to the previously placed hemostatic sutures. After excision of the lesion, the hemostatic sutures were removed, and a straight-line closure of the scalp was performed in layers. Follow-up 10 months later demonstrates a well-healed incision with the ear in its normal position (Fig. 5).

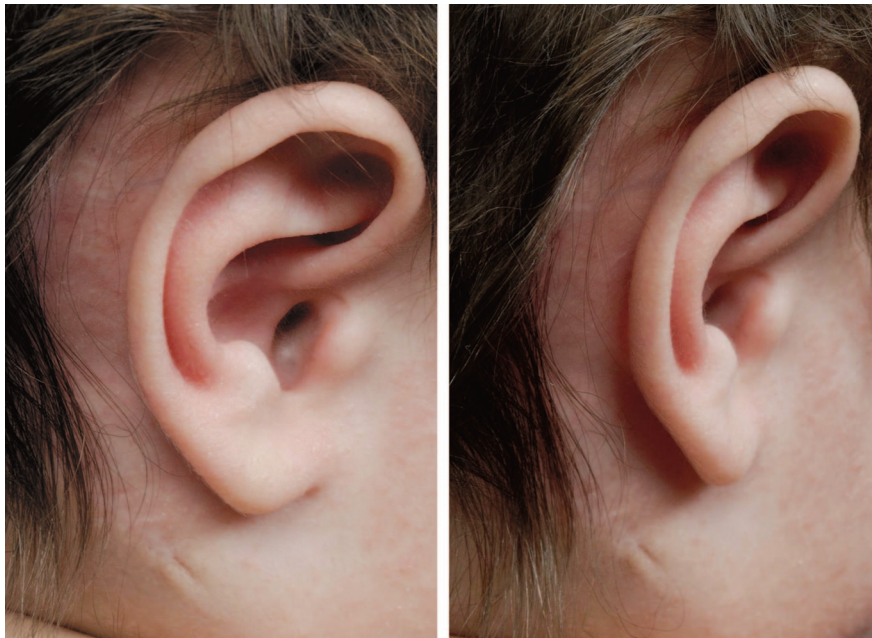
#### Case 5

A 3-month-old girl presented with an enlarging hemangioma ( $4 \times 4$  cm) immediately superior and posterior to the right ear resulting in significant deformation of that ear (Fig. 6, *left*).

After infiltrating the local tissues as described above, an incision was extended from the base of the lesion posteriorly



**Fig. 4.** Case 4. Photograph of a large postauricular hemangioma causing anterior displacement of the ear.



**Fig. 5.** Postoperatively, the ear has resumed its normal position. Also, note the scar well hidden within the hairline.

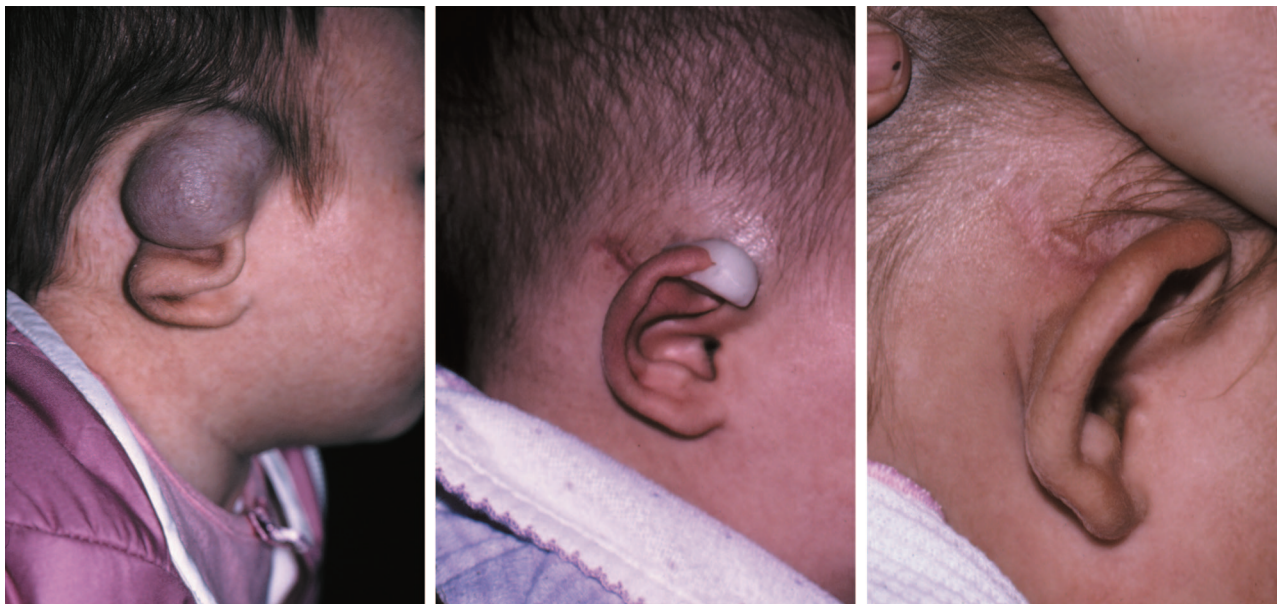into the auriculocephalic crease. The hemangioma was excised by dissection above the temporal fascia. The remaining defect was closed tension-free by simple undermining and advancement of the local tissues. Postoperatively, the superior portion of the ear was molded using Aquaplast for 3 weeks (Fig. 6, center). Both the resulting scar and the final ear shape were aesthetically acceptable (Fig. 6, right).

#### Case 6

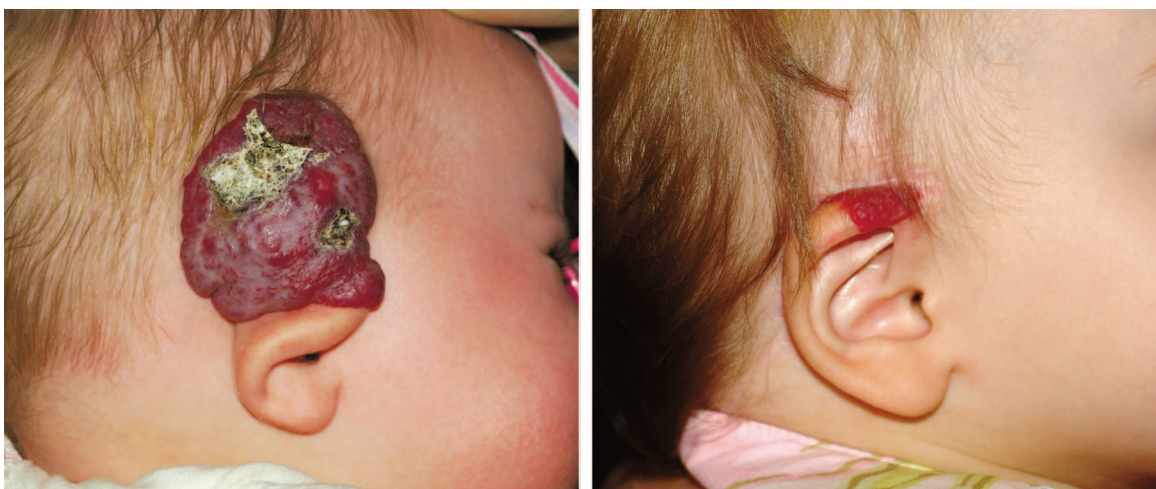A 6-month-old girl presented for evaluation of a large ulcerated hemangioma, approximately  $5 \times 6$  cm, positioned just superior to the right ear with extension onto the upper aspect

of the helix. The lesion was painful and causing significant deformity of the infant's right ear (Fig. 7, left).

As in previous cases, the area underneath the lesion was infiltrated with a tumescent epinephrine-containing solution. The lesion was excised with minimal blood loss and a superiorly based occipital scalp flap was rotated into the defect. A small backcut was required to allow for tension-free closure. Immediately on removal of the lesion, the position of the ear improved. The small (nondeforming) portion of the hemangioma that extended onto the helix itself was left in place to involute (Fig. 7, right).



**Fig. 6.** Case 5. (Left) Photograph of a large hemangioma of the temporoparietal region causing significant deformity of the ear. (Center) Postoperative view showing the Aquaplast mold (Sammons Preston, Boilingbrook, Ill.) in place. (Right) Final postoperative appearance. The ear deformity has been corrected and the scar is well hidden.



**Fig. 7.** Case 6. (Left) Photograph of a large ulcerating hemangioma just above and extending onto the right ear. Note the “push-down” deformity. (Right) View of the ear after excision. Note the small portion of the lesion left on the helix to involute.

## DISCUSSION

The “treatment” of hemangiomas, the most common tumor of infancy, is as varied as the location of its presentation. Most pediatricians and even many plastic surgeons will counsel watchful waiting of the lesion as it progresses through the usual stages of proliferation and (variable) involution. Although patience may be virtuous for many hemangiomas, we feel that large hemangiomas of the scalp deserve special scrutiny.

Besides the commonly accepted reasons for surgical intervention (e.g., ulceration, hemodynamic instability, airway obstruction), large (and even not so large) hemangiomas of the scalp may invite a more aggressive surgical approach for the following reasons. First, even if a hemangioma undergoes complete involution, the remaining fibrofatty skin is often atrophic.<sup>3</sup> The dermal layer is extremely thin and devoid of normal skin appendages. This can lead to large alopecic areas

and/or derangement of the natural hairline. As demonstrated in case 2, a cosmetically appropriate anterior hairline was recreated after excising a large hemangioma of the anterior scalp and forehead. In part, because this patient did not present until 18 months of age, tissue expansion was required to provide sufficient tissue for closure.

Second, hemangiomas of the parietal scalp may impinge on the ear. Because of the well-known pliability of the neonatal ear, thought to be secondary to the effects of maternal estrogens, extrinsic deforming forces may result in a permanent deformity. Thus, there is an opportunity to both remove the deforming force and reshape the ear within an early postpartum window of opportunity.<sup>8,9</sup> As demonstrated in cases 4 through 6, permanent ear deformity was avoided by early removal of the deforming hemangioma.

Finally and perhaps most importantly, the scalp of a newborn infant possesses significant elasticity because of a relative “tissue excess” and an inherent pliability resulting from the absence of a thick fibrous galeal layer.<sup>7</sup> As the infant ages, this considerable redundancy of scalp tissue dissipates, which may limit the possibility of primary closure (with or without scalp rotation flaps) without the need for tissue expansion. It should be noted that in the case of neonates born prematurely, the optimal timing for surgical intervention needs to be considered individually, as the relative operative risk will vary with the degree of prematurity.

Although traditionally there has been concern that excision of hemangiomas in infants can be associated with life-threatening bleeding, three important technical points are emphasized to minimize this risk. First, all excisions are performed only after infiltrating the lesion and surrounding tissues with a “tumescent” solution of dilute epinephrine. Second, hemostatic polypropylene sutures may be placed around the hemangioma to limit inflow to the lesion. Third, the plane of dissection is *outside* of the lesion in the avascular galeal layer. Although bleeding of any amount in an infant is potentially dangerous, ap-

plication of these simple principles will reduce the chance of a potentially disastrous hemorrhage.

## CONCLUSIONS

Although many hemangiomas will involute and be benign in evolution, some scalp lesions can be large, deforming, ulcerative, and predisposed to hairless zones. Because of an inherent laxity of the scalp found only up to age 4 months, early intervention may be wise by allowing the surgeon to correct all negative sequelae with total removal using very simple methods. We present six cases that outline our *modus operandi*.

Barry M. Zide, D.M.D., M.D.  
420 East 55th Street, Suite 1D  
New York, N.Y. 10022  
barry.zide@med.nyu.edu

## REFERENCES

1. Mulliken, J. B., and Glowacki, J. Hemangiomas and vascular malformations in infants and children: A classification based on endothelial characteristics. *Plast. Reconstr. Surg.* 69: 412, 1982.
2. Bowers, R., Graham, E. A., and Tomlinson, K. M. The natural history of the strawberry nevus. *Arch. Dermatol.* 82: 667, 1960.
3. Werner, J. A., Dunne, A. A., Folz, B. J., et al. Current concepts in the classification, diagnosis and treatment of hemangiomas and vascular malformations of the head and neck. *Eur. Arch. Otorhinolaryngol.* 258: 141, 2001.
4. Bauman, N. M., Burke, D. K., and Smith, R. J. Treatment of massive or life-threatening hemangiomas with recombinant alpha(2a)-interferon. *Otolaryngol. Head Neck Surg.* 117: 99, 1997.
5. Achauer, B. M., Chang, C. J., and Vander Kam, V. M. Management of hemangioma of infancy: Review of 245 patients. *Plast. Reconstr. Surg.* 99: 1301, 1997.
6. Hsiao, C. H., Tsao, P. N., Hsieh, W. S., et al. Huge, alarming congenital hemangioma of the scalp presenting as heart failure and Kasabach-Merritt syndrome: A case report. *Eur. J. Pediatr.* 166: 619, 2007.
7. Picard, A., Franchi, G., Delbecque, M., et al. Scalp surgery in children: Principles and therapeutic aspects (in French). *Rev. Stomatol. Chir. Maxillofac.* 106: 334, 2005.
8. Kurozumi, N., Ono, S., and Ishida, H. Non-surgical correction of a congenital lop ear deformity by splinting with Reston foam. *Br. J. Plast. Surg.* 35: 181, 1982.
9. Yotsuyanagi, T., Yokoi, K., Urushidate, S., et al. Nonsurgical correction of congenital auricular deformities in children older than early neonates. *Plast. Reconstr. Surg.* 101: 907, 1998.